

# The Brissaud sign

## O sinal de Brissaud

Tiago Aguiar<sup>1</sup>, Péricles Maranhão-Filho<sup>1,2</sup>

A 65-year-old man has a three-month history of lumbar back pain and progressive lower extremity weakness due a T6 spinal cord compression secondary to hepatic metastatic carcinoma. Examination revealed, paraplegia, urinary incontinence, T10 sensory level, lower limbs hyperactive deep reflex, and hallux indifferent cutaneous plantar response

but with an exuberant fascia lata reflex (Figure). The Brissaud sign<sup>1</sup>, a succedaneum published only 22 days after Babinski's famous lecture, is a twitch in the lateral portion of the quadriceps muscle on tickling the sole of the foot and represents a proximal component of the flexion reflex synergy owing to pyramidal tract disfunction<sup>2</sup>.

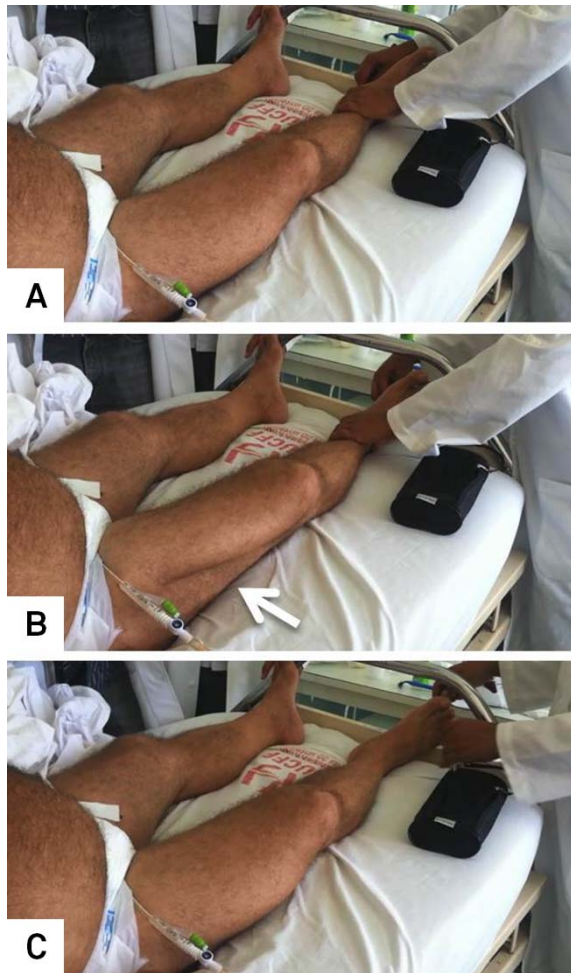


Figure. Right plantar cutaneous stimulation. In the beginning (A). Right fascia lata muscle contraction (Brissaud sign) (arrow) (B), at the end and (amazing) without Babinski sign. (Images taken from movie).

## References

1. Brissaud E. Le réflexe du fascia lata. *Gaz Hebdo Méd Chirurg* 1896;43:253-256.
2. J. van Gijn. The Babinski sign - a centenary. Universiteit Utrecht (publicatation dept.) Utrecht. Netherlands. 1996:83.

<sup>1</sup>Departamento de Neurologia, Hospital Universitário Clementino Fraga Filho, Universidade Federal do Rio de Janeiro, Rio de Janeiro RJ, Brazil;

<sup>2</sup>Instituto Nacional de Câncer, Rio de Janeiro RJ, Brazil.

**Correspondence:** Tiago Aguiar; Av. Brigadeiro Trompowski s/n; 21941-590 Rio de Janeiro RJ; Brasil; E-mail: tiagosaguiar@gmail.com

**Conflict of interest:** There is no conflict of interest to declare.

Received 14 October 2013; Received in final form 17 January 2014; Accepted 07 February 2014.