

Paradoxical Worsening of Brain Tuberculomas During Treatment

AN 8-YEAR-OLD BOY being treated with chemotherapy owing to stage IIIA Hodgkin disease was admitted to the pediatric intensive care unit because of fever and respiratory distress in the previous 2 weeks. Despite full antibiotic coverage, his condition worsened, and 7 days later, he underwent a lung biopsy. On the next day, he developed headache, vomiting, and progressive coma. A brain magnetic resonance image showed multiple small, round T2-weighted and fluid-attenuated inversion recovery hyperintense lesions (Figure, A) suggestive of brain tuberculomas. A lumbar puncture revealed a white blood cell count of 10 cells/mm³, protein level of 40 mg/dL, and glucose level of 37 mg/dL. Stains and culture results for bacteria, mycobacteria, and fungi were negative as well as cerebrospinal fluid *Mycobacterium tuberculosis* polymerase chain reaction. Tuberculosis was diagnosed from the lung biopsy specimen and the patient gradually improved after starting treatment with rifampicin, ethambutol hydrochloride, streptomycin, and pyrazinamide.

He was discharged home 3 weeks later, but 1 week after, he presented with new onset of headache, vomiting, low-grade fever, and mild right hemiparesis. A new brain magnetic resonance image disclosed worsening of the swelling around the tuberculomas (Figure, B), and a diagnosis of paradoxical reaction to tuberculosis was made. Neurological symptoms disappeared after 2 weeks of steroid treatment. Five months later, all brain lesions had disappeared on a follow-up magnetic resonance image (Figure, C).

COMMENT

Brain tuberculomas are caseous foci with fibrous encapsulation resulting from hematogenous dissemination.¹ They are present in the brain of 1% of patients with active tuberculosis² and can occur independently of meningeal involvement, as observed in our patient. Paradoxically, tuberculomas can develop or enlarge during therapy, leading to new neurological complaints, mainly focal signs or symptoms of increased intracranial pressure. The mechanism behind this process is yet to be defined, but some authors believe that improvement of the host cellular immune response after antituberculous treatment may have a role.³ Another theory implies the massive release of components of the acid-fast bacilli (peptidoglycan and mucopeptide) soon after starting treatment, which leads to an inflammatory reaction. Similar hypersensitivity manifestations may be also observed in other infections such as syphilis (Jarisch-Herxheimer reaction).

Paradoxical worsening of tuberculomas should not be confounded with failed treatment. The lesions may grow or appear de novo on serial imaging studies, improving thereafter, while failed treatment is often associated with resistant *M tuberculosis* strains on drug susceptibility tests. Antituberculous drugs do not need to be discontinued in patients with paradoxical reactions, and steroids are useful to manage increased intracranial pressure in symptomatic patients. Thalidomide may be effective for refractory cases.⁴

Marco A. Lima, MD, PhD
Péricles Maranhão-Filho, MD, PhD
Jane Dobbin, MD
Alexandre Gustavo Apa, MD
Gabriela A. Lima, MD
Eduardo Velasco, MD, PhD
Clemax Couto Sant'Anna, MD

Author Affiliations: Departments of Neurosurgery (Drs M. A. Lima and Maranhão-Filho), Hematology (Drs Dobbin and Apa), Radiology (Dr G. A. Lima), and Infectious Diseases, National Institute of Cancer (Dr Velasco), and Department of Pediatrics, Federal University of Rio de Janeiro (Dr Sant'Anna), Rio de Janeiro, Brazil.

Correspondence: Dr M. A. Lima, Avenida Alexandre Ferreira, 420 Apt 403, Lagoa, Rio de Janeiro, RJ 22470-220, Brazil (mlima@inca.gov.br).

Author Contributions: Study concept and design: M. A. Lima and Maranhão-Filho. Acquisition of data: Apa, Lima, Velasco, and Sant'Anna. Analysis and interpretation of data: M. A. Lima, Maranhão-Filho, and Dobbin. Drafting of the manuscript: M. A. Lima. Critical revision of the manuscript for important intellectual content: Maranhão-Filho, Dobbin, Apa, Lima, Velasco, and Sant'Anna.

Financial Disclosure: None reported.

REFERENCES

1. Afghani B, Lieberman JM. Paradoxical enlargement or development of intracranial tuberculomas during therapy: case report and review. *Clin Infect Dis*. 1994;19(6):1092-1099.
2. Kumar R. Atypical response to chemotherapy in neurotuberculosis. *Br J Neurosurg*. 1998;12(4):344-348.
3. Nicolls DJ, King M, Holland D, Bala J, del Rio C. Intracranial tuberculomas developing while on therapy for pulmonary tuberculosis. *Lancet Infect Dis*. 2005;5(12):795-801.
4. Roberts MT, Mendelson M, Meyer P, Carmichael A, Lever AM. The use of thalidomide in the treatment of intracranial tuberculomas in adults: two case reports. *J Infect*. 2003;47(3):251-255.

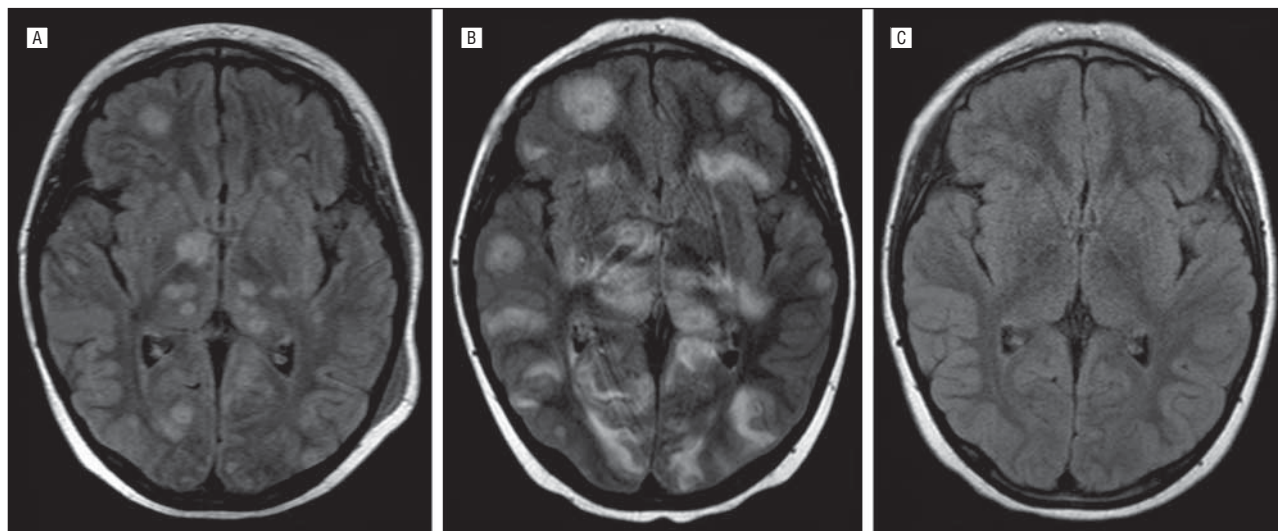


Figure. Axial fluid-attenuated inversion recovery magnetic resonance imaging sequences. A, Multiple brain tuberculomas at the time of diagnosis. B, One month after treatment, there was enlargement of the lesions, worsening of the surrounding edema, and the development of new lesions. C, Five months later, a new scan showed disappearance of the lesions.